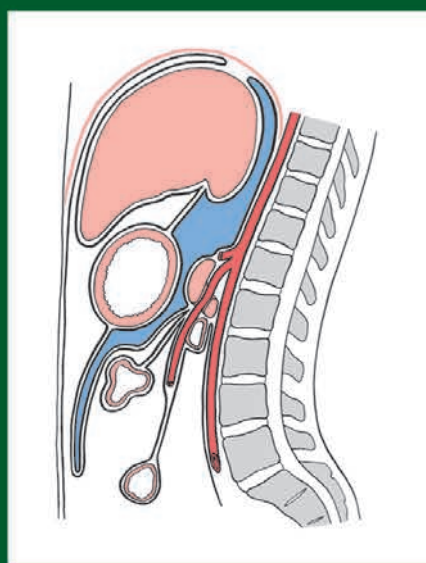
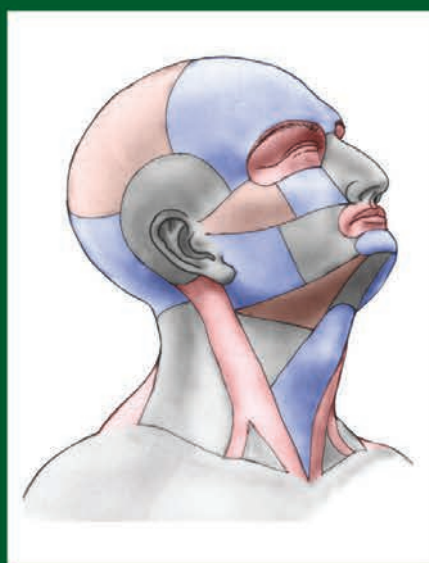


Josef Stingl, Miloš Grim, Rastislav Druga

REGIONAL ANATOMY



Karolinum
Galén

Upozornění

Všechna práva vyhrazena.

Žádná část této tištěné či elektronické knihy nesmí být reprodukována a šířena v papírové, elektronické či jiné podobě bez předchozího písemného souhlasu nakladatele.

Neoprávněné užití této knihy bude trestně stíháno.

Galén

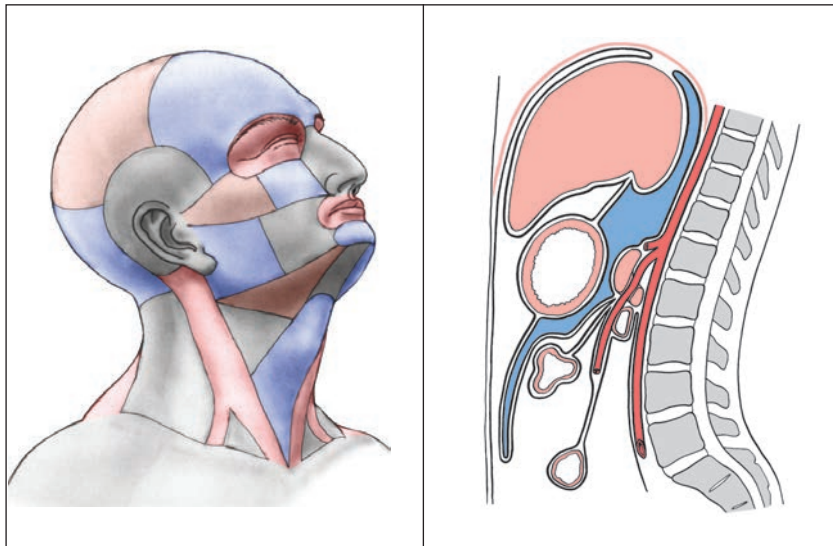
Na Bělidle 34, 150 00 Praha 5

www.galen.cz

© Galén, 2012

Josef Stingl, Miloš Grim, Rastislav Druga

REGIONAL ANATOMY



**Karolinum
Galén**

Přeloženo z českého originálu

Miloš Grim, Rastislav Druga et al. Základy anatomie.

Josef Stingl, Miloš Grim, Rastislav Druga. 5. Anatomie krajiny těla. Praha: Galén–Karolinum 2002 a 2008.

Autoři

prof. MUDr. Josef Stingl, CSc. / Anatomický ústav, 3. lékařská fakulta, Univerzita Karlova v Praze

prof. MUDr. Miloš Grim, DrSc. / Anatomický ústav, 1. lékařská fakulta, Univerzita Karlova v Praze

prof. MUDr. Rastislav Druga, DrSc. / Anatomický ústav, 2. lékařská fakulta, Univerzita Karlova v Praze

Recenzenti českého vydání

prof. MUDr. Radomír Čihák, DrSc. / Anatomický ústav, 1. lékařská fakulta, Univerzita Karlova v Praze

prof. MUDr. Pavel Pafko, DrSc. / III. chirurgická klinika, 1. lékařská fakulta, Univerzita Karlova v Praze, FN v Motole

Ilustrace

Mgr. Jan Kacvinský

akad. mal. Ivan Helekal

Anatomický ústav, 1. lékařská fakulta, Univerzita Karlova v Praze

Stanislav Macháček

Překladatelé do angličtiny

prof. MUDr. David Sedmera, DSc., editor anglického překladu

Mgr. Jana Bednářová

MUDr. Zdeněk Fík

MUDr. Ivo Klepáček, CSc.

MUDr. Ondřej Kodet

Marek Kolár

MUDr. Lukáš Lacina, Ph.D.

MUDr. Veronika Němcová, CSc.

MUDr. Živorad Peševski

Kristýna Špillerová

doc. MUDr. Petr Valášek, Ph.D.

Anatomický ústav, 1. lékařská fakulta, Univerzita Karlova v Praze

Odborná jazyková revize

Natasha Agabalyan / University of Sussex, Brighton, United Kingdom

Knižní vydání / 2012

Nakladatelství Galén, Na Bělidle 34, 150 00 Praha 5

a Univerzita Karlova v Praze, nakladatelství Karolinum, Ovocný trh 3-5, 116 36 Praha 1

Josef Stingl, Miloš Grim, Rastislav Druga

REGIONAL ANATOMY

První vydání v elektronické verzi

Vydalo nakladatelství Galén, Na Bělidle 34, 150 00 Praha 5

Editor nakladatelství PhDr. Lubomír Houdek

Šéfredaktorka nakladatelství PhDr. Soňa Dernerová

Odpovědný redaktor Mgr. Radek Lunga

Sazba Milena Honců, DTP Galén

G 311070

Všechna práva vyhrazena.

Tato publikace ani žádná její část nesmějí být reprodukovány, uchovávány v rešeršním systému

nebo přenášeny jakýmkoli způsobem (včetně mechanického, elektronického, fotografického či jiného záznamu) bez písemného souhlasu nakladatelství.

© Galén, 2012

ISBN 978-80-7262-931-2 (PDF)

ISBN 978-80-7262-932-9 (PDF pro čtečky)

Contents

Foreword	7	3 Regions of the trunk, regiones trunci	
1 Regions of the head, regiones capitis		3.1 Regions of the chest	43
1.1 The brain case	9	3.1.1 Topography of the thoracic wall	44
1.1.1 Frontal, parietal and temporal region	9	3.1.2 Presternal region	45
Vascular and nerve supply to the scalp	10	3.1.3 Pectoral region, clavipectoral triangle.....	46
1.1.2 External surface of the cranial base.....	11	3.1.4 Pleural cavities.....	48
1.1.3 Internal surface of the cranial base.....	11	Boundaries of the pleura and their projection	
1.2 Superficial regions of the face	14	on the chest surface	49
1.2.1 Orbital region	14	Boundaries and projection of the lungs	
1.2.2 Nasal region.....	15	on the chest surface	50
1.2.3 Oral region.....	15	Projection of the heart.....	50
1.2.4 Buccal region.....	17	3.1.5 Mediastinum.....	52
1.2.5 Parotidomasseteric region	19	Superior mediastinum.....	52
1.2.6 Mental region	19	Inferior anterior mediastinum	57
1.3 Deep regions of the face	19	Inferior middle mediastinum.....	57
1.3.1 Infratemporal region	19	Inferior posterior mediastinum	57
1.3.2 Pterygopalatine fossa.....	22	3.2 Regions of the abdomen	57
1.3.3 Pterygomandibular space	22	3.2.1 Projection of organs onto the anterior	
1.3.4 Parapharyngeal space	22	abdominal wall	58
1.3.5 Retropharyngeal space	22	3.2.2 Abdominal wall structure	59
1.3.6 The orbit	22	3.2.3 Inguinal region, the groin	61
Orbital content	24	3.2.4 Peritoneal cavity	62
1.3.7 Nasal cavity.....	26	3.2.4.1 Supramesocolic part of the peritoneal	
1.3.8 Oral cavity.....	27	cavity.....	62
1.3.9 Tonsillar region	29	■ Lesser sac	64
1.3.10 Sublingual region	29	■ Position and syntopy of the liver	64
2 Regions of the neck, regiones cervicales		■ Position and syntopy of the gallbladder	
2.1 Anterior triangle of the neck	31	and the biliary ducts.....	65
2.1.1 Muscular triangle (omotracheal).....	31	■ Syntopy of the abdominal oesophagus.....	67
2.1.2 Submandibular triangle, digastric triangle.....	36	■ Position and syntopy of the stomach.....	67
2.1.3 Submental triangle.....	39	■ Position and syntopy of the spleen.....	67
2.1.4 Carotid triangle.....	39	■ Position and syntopy of the duodenum ...	67
2.1.5 Sternocleidomastoid region.....	41	■ Position and syntopy of the pancreas	69
2.1.6 Scalenovertbral triangle	42	3.2.4.2 Inframesocolic part of the peritoneal cavity ...	71
2.2 Lateral region of the neck	42	■ Right inframesocolic space	73
		■ Left inframesocolic space	73
		■ Organs in the inframesocolic space	73
		3.2.5 Retroperitoneum.....	75
		■ The middle part of the retroperitoneal	
		space	75

■ The lateral part of the retroperitoneal space.....	75	4.6	Regions of forearm.....	101
3.3	Regions of the pelvis.....	77	■ Anterior antebrachial region.....	101
3.3.1	Position and syntopy of the urinary bladder..	77	■ Posterior antebrachial region.....	102
3.3.2	Position and syntopy of the rectum.....	78	4.7	Wrist regions.....
3.3.3	Topography of the male pelvis.....	79	■ Anterior carpal region.....	103
3.3.4	Topography of the female pelvis.....	80	■ Posterior carpal region.....	105
3.3.5	Perineal regions.....	81	4.8	Palmar region.....
■ Male urogenital region.....	82	4.9	Dorsum of the hand.....	107
■ Female urogenital region.....	83	4.10	The fingers.....	107
■ Anal region.....	84			
■ Ischioanal (ischiorectal) fossa.....	85	5	Regions of lower limb, regiones membri inferioris	
3.4	Regions of the back and nuchal regions.....	86	5.1	Gluteal region.....
3.4.1	Dorsal regions.....	86	5.2	Femoral regions.....
3.4.2	Posterior cervical (nuchal) region.....	86	■ Anterior femoral region.....	110
3.4.3	Vertebral and sacral region.....	90	■ Posterior femoral region.....	114
■ Topography of the vertebral canal.....	90	5.3	Knee regions.....	115
3.4.4	Lumbar region.....	90	■ Anterior knee region.....	115
			■ Posterior knee region (popliteal fossa)....	116
4	Regions of the upper limb, regiones membri superioris		5.4	Leg regions.....
4.1	Scapular region.....	93	■ Anterior crural region.....	117
4.2	Deltoid region.....	93	■ Posterior crural region, the calf.....	118
4.3	The axilla.....	95	5.5	Retromalleolar regions.....
4.4	Anterior and posterior region of the arm....	98	■ Medial retromalleolar region.....	119
4.5	Elbow regions.....	99	■ Lateral retromalleolar region.....	119
■ Anterior cubital region.....	99	5.6	Dorsum of the foot.....	120
■ Posterior cubital region.....	101	5.7	Sole of the foot.....	121
		5.8	The toes.....	122

Foreword

The Czech version of Basic Anatomy, Volume 5, dedicated to the memory of Prof. Karel Weigner (1874–1937), chair of the Institute of Anatomy in Prague and founder of Czech regional and clinical anatomy, is part of a five-volume textbook of anatomy for first year medical students. Since its publication, this series has gained a lot of popularity among students of the systems-based curriculum for its convenient format, clear figures and concise text. While the main benefit of the organ system-based teaching method is its clear connection with microscopic anatomy, physiology and clinical specialties, topographic approach needs an integrative component that puts all the structures together in a region-oriented way. This is the main objective of this volume covering Topographic Anatomy.

Most English anatomy textbooks are region-based because of the prevalence of a regionally-oriented curriculum in the US. One might rightfully ask what makes this volume stand out in comparison. In fact, the translation was prompted by repeated prodding of our English-taught medical students, who wanted the same textbook their Czech colleagues were using during the dissections and preparations for the final examination. While we provided online translation of some of the most commonly used figures, it still did not satisfy their longing for a full text.

Comparing the external appearance of this book with that of most frequently used volumes (Gray's Anatomy for Students, Moore's Clinically Oriented Anatomy or Snell's Clinical Anatomy), the main difference seems to lie in its size: it is several times smaller than the other volumes in both thickness and weight. This is due to a deliberate omission of

detailed description of the individual organs which was already provided in the Systems Anatomy.

This book focuses on the relationships between varied organs as encountered during the dissection course, making it a useful tool during this highly enriching, but also stressful time. The description of key anatomical regions is supplemented by ample coloured schematic drawings and often complemented by matched radiographic images. The book follows the dissection of a human body from head to toe, providing external landmarks and superficial anatomy, as well as detailed descriptions of the structures. Key points of clinical implications are highlighted in gray boxes. A lot of emphasis has been put on cross-sectional anatomy, as it is the way in which the students will encounter the human body in the future. Three dimensional integration of knowledge gained during dissection with these imaging modalities (CT, MRI) is a must for functional understanding of the human body not only for surgery, but also for other branches of medicine.

We sincerely hope that the English-speaking students will find this book as useful as our Czech students, and wish all of them success on their path to become medical doctors.

Prague, December 2011

Milos Grim

(for the authors of the original Czech version)

David Sedmera

(for the team of translators)

1 Regions of the head, *regiones capitis*

The head can be subdivided into *neurocranium* (the calvaria) and *splanchnocranium* (the face). It is defined from the neck by a conventional line running from the external occipital protuberance across the superior nuchal line towards the external acoustic meatus and then along the posterior and inferior border of the lower jaw to the midline in the mental region. The border between the brain case and face is the line running from the external acoustic meatus anteriorly along the zygomatic arch and eyebrows to the glabella. In the depth, these two regions are separated by the external cranial base.

In the brain case are first described the superficial regions and then the cranial base. In the facial region of the head are also first found the superficial regions followed by the orbital, nasal and oral cavities and finally infratemporal and pterygo-palatine fossa and related regions.

1.1 The brain case

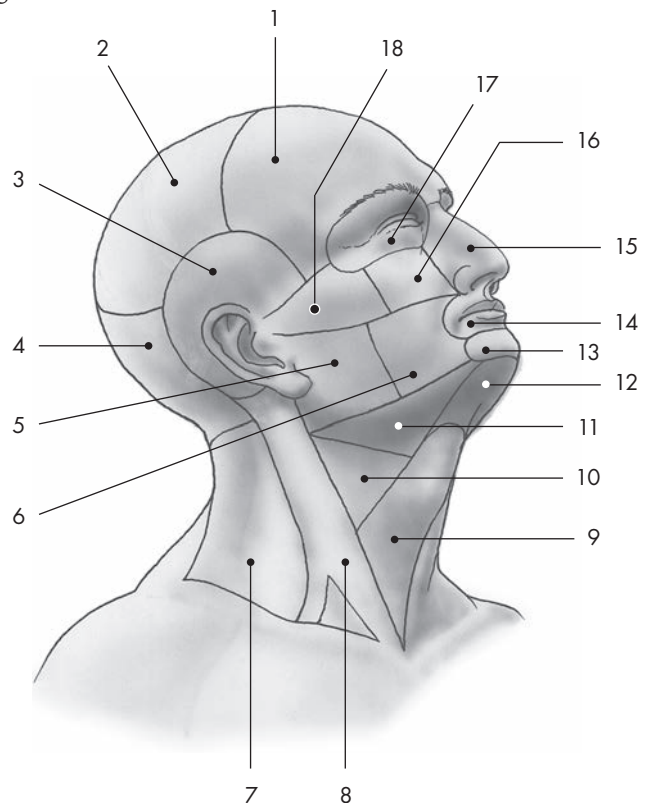
The skeleton of the brain case is composed of the cranial vault, the *calvaria* (the skull cap) and the *basicranium* (the cranial base).

1.1.1 Frontal, parietal and temporal region

These regions (Fig. 1.1) correspond to underlying bones of the same names. Because the arrangement of the layers in these regions is similar, they are de-

Fig. 1.1 Overview of regions of the head and neck.

- 1 - frontal region
- 2 - parietal region
- 3 - temporal region
- 4 - occipital region
- 5 - parotideomasseteric region
- 6 - buccal region
- 7 - lateral cervical region
- 8 - sternocleidomastoid region
- 9 - muscular triangle
- 10 - carotid triangle
- 11 - submandibular triangle
- 12 - submental region
- 13 - mental region
- 14 - oral region
- 15 - nasal region
- 16 - infraorbital region
- 17 - orbital region
- 18 - zygomatic region



scribed together. Their base is formed by the cranial vault, the *calvaria*, covered by soft tissues – the **scalp** (Fig. 1.2).

The principal layers are formed by:

- Skin, which is very thick, and normally covered by hair;
- Subcutaneous connective tissue, with a large amount of fibrous bundles that connect the deep layer of the skin with the galea aponeurotica. This arrangement allows only minimal movement of skin against the galea aponeurotica. In the subcutaneous tissue are found thin walled veins that frequently gape when injured, causing profuse bleeding;
- Galea aponeurotica, a layer of dense connective tissue into which different parts of the epicranial muscle insert: occipitofrontal and temporoparietal. It is also sometimes called the epicranial aponeurosis;
- Loose connective tissue under the galea which allows large movements of the skin and galea aponeurotica against the periosteum. This can also be a site of large hematomas after blunt skin trauma;
- Periosteum, the fibrous layer covering the bones of the cranial vault.

In the temporal region, underneath the temporo-parietal muscle, is the temporalis muscle, covered by strong temporalis fascia. This fascia has two layers that run from the inner to the outer border of the zygomatic arch and fuse together superiorly where the muscle attaches to the superior temporal line. Between these two layers is a layer of fatty tissue.

The periosteum covering the bones of the cranial vault is called the pericranium. It can easily be peeled off the bones in the newborn child, but is firmly adhered in the adult, particularly in areas of cranial sutures.

The wounds that do not penetrate the galea aponeurotica do not gape greatly; in contrast, the wounds penetrating into the sub-galeal connective tissue do gape. Separation of the hairy skin together with the galea is called the scalping injury.

Vascular and nerve supply to the scalp

The frontal region is supplied by the branches of the **supraorbital** and **supratrochlear** artery (Fig. 1.5). There are rich anastomoses positioned laterally to the branches of the zygomatico-orbital and superficial temporal arteries. The temporal region is supplied by

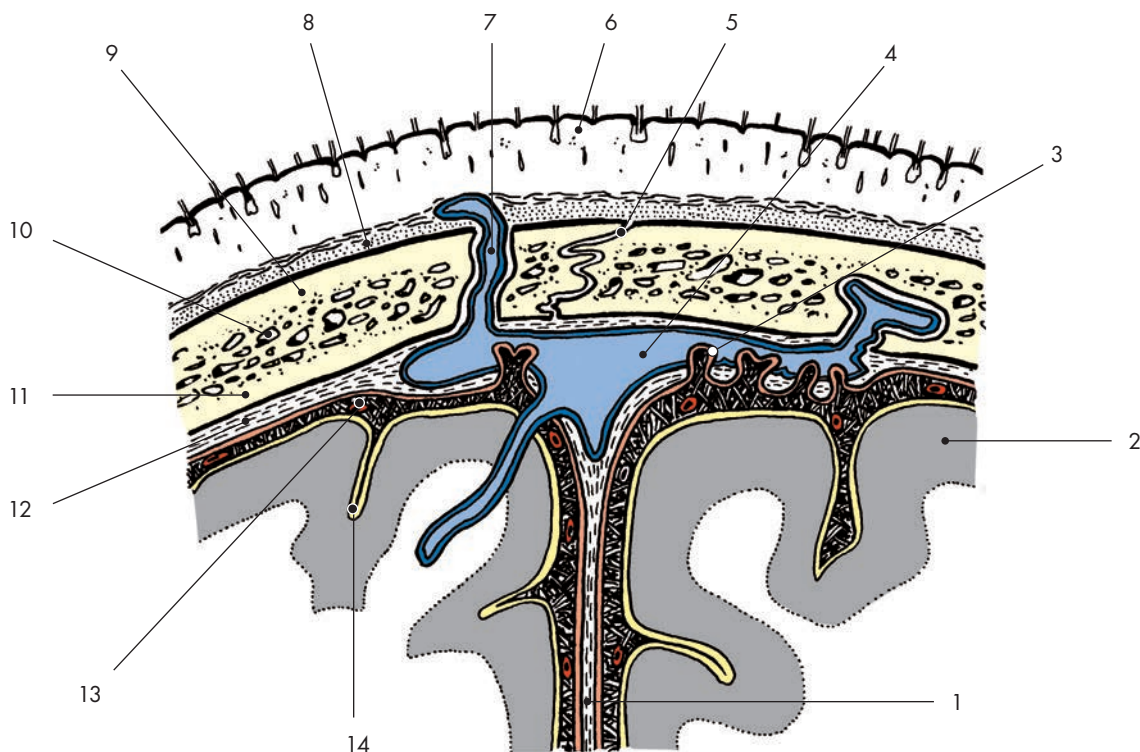


Fig. 1.2 Frontal section showing the soft tissues of the head, the bones of the cranial vault and brain coverings. 1 – falx cerebri, 2 – cerebral cortex, 3 – arachnoid granulations, 4 – superior sagittal sinus, 5 – sagittal suture, 6 – skin, 7 – emissary vein, 8 – pericranium (periosteum), 9 – outer compact layer, 10 – diploe, 11 – inner compact layer, 12 – dura mater, 13 – subarachnoid space, 14 – pia mater

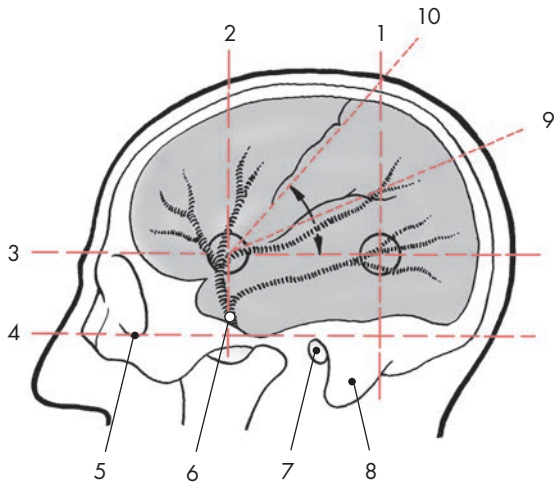


Fig. 1.3 Projection of the anterior and posterior branches of the middle meningeal artery (circles) and central and lateral sulcus of the brain.

1 - perpendicular line through the posterior edge of the mastoid process (intercepts line no. 3 in the posterior point of Krönlein), 2 - perpendicular line through the centre of the zygomatic arch (intercepts line no. 3 in the anterior point of Krönlein), 3 - line parallel with the auriculoorbital line passing through the superior rim of the orbit, 4 - auriculoorbital line (so-called Frankfurt horizontal) passing through the inferior rim of the orbit (5) and the upper rim of the external acoustic meatus, 5 - lower rim of the orbit, 6 - entrance of the middle meningeal artery to the skull through the foramen spinosum, 7 - external acoustic meatus, 8 - mastoid process, 9 - projection of the lateral sulcus of the brain (the line of projection splits the angle between lines 3 and 10 in half), 10 - approximate projection of the central sulcus of the brain (line connecting the anterior point of Krönlein with the point of intersection of the vertical line number 1

the branches of **superficial temporal artery**, which splits above the auricle into frontal and parietal branches. Its pulsations can be palpated against the bone. Underneath the temporalis muscle run the deep temporal arteries and nerves. Blood supply of the occipital region is provided by the **occipital artery** (Fig. 1.7).

The **veins** of the scalp empty anteriorly into the veins of the orbit, laterally into the superficial temporal vein and the pterygoid plexus, and from the occipital region into the external jugular vein.

Lymphatics from the frontal and temporal region drain into the parotid lymphatic nodes, from the temporoparietal region into the retroauricular lymph nodes and from the occipital region into the occipital lymph nodes.

Motor innervation of the entire epicranium muscle as well as the muscles of the auricles is provided by the facial nerve. The temporalis muscle is innervated by the third division of the trigeminal nerve.

Sensory innervation of the skin is provided anteriorly up to the interauricular line by the trigeminal

nerve via the supraorbital, auriculotemporal and zygomaticotemporal branch of the zygomatic nerve. Behind the interauricular line, it is provided by the great auricular and the greater and lesser occipital nerves (Fig. 1.7).

The **cranial vault** proper, the **calvaria**, is formed by the parietal bones, squamous parts of the frontal, occipital and temporal bones, and greater wings of the sphenoid bone. It is thinnest in its temporal and parietal regions, whereas anteriorly and posteriorly it is more robust. The bones of the cranial vault are composed of the outer and inner compact layers with a spongy bone called the diploe between them (Fig. 1.2). The venous blood from the diploe drains through the diploic veins to the dural sinuses. Anteriorly, the frontal bone shows variable pneumatization by often asymmetric frontal sinuses. In the temporal region run the branches of the middle meningeal vessels on the inner aspect of the vault (Fig. 1.3).

Bleeding from torn meningeal vessels causes epidural hematoma.

The deepest layer of these regions is the dura mater of the brain, which adheres to the bones from the bottom and is stuck to their periosteum. In between the dura and the periosteum are the dural venous sinuses: the superior sagittal sinus, the confluence of the sinuses, the transverse sinus, and the occipital sinus (Figs. 1.2 and 1.4).

1.1.2 External surface of the cranial base

The lower aspect of the cranial base, **basis cranii externa**, borders underneath the anterior cranial fossa with the spaces of the splanchnocranium, the nasal cavity and the orbit. Underneath the middle cranial fossa there is in the center the sphenoidal sinus and lateral to the cartilaginous part of the nasopharyngeal (Eustachian) tube, the pterygopalatine fossa, the infratemporal fossa and the temporomandibular joint. Underneath the posterior cranial fossa is the attachment of the pharynx and the middle and parapharyngeal space. Behind the pharynx lie the atlantooccipital joint and the attachments of the deep nuchal muscles.

1.1.3 Internal surface of the cranial base

The upper aspect of the cranial base, **basis cranii interna** (Fig. 1.4), is covered with the dura mater and is subdivided into three cranial fossae:

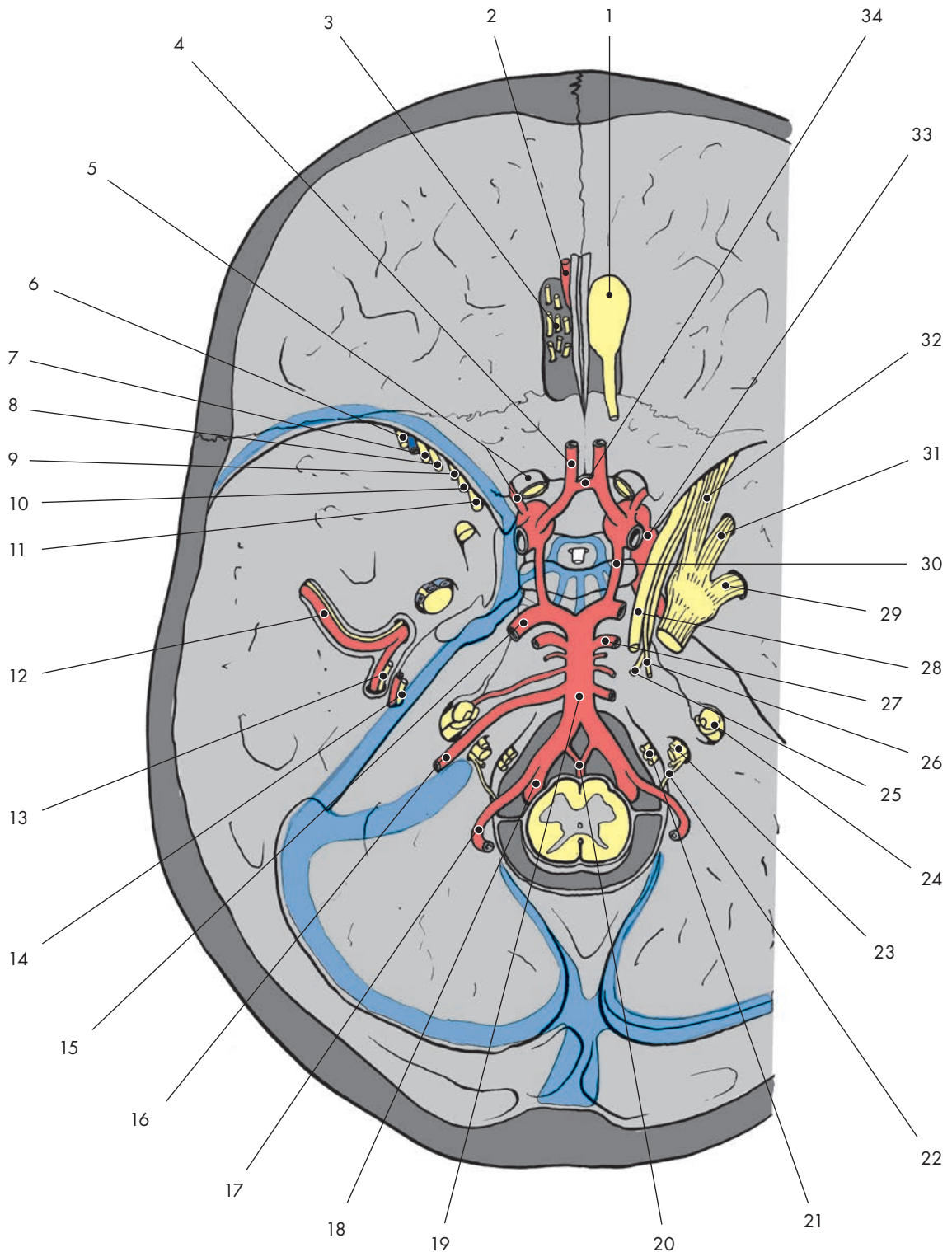


Fig. 1.4 Interior of the base of the skull, basis cranii interna (blue marks the position of the sinus durae matris, with the dura mater partially removed). 1 - olfactory bulb, 2 - anterior meningeal artery, branch of the anterior ethmoidal artery, 3 - olfactory nerves, 4 - anterior cerebral artery, 5 - optic nerve and ophthalmic artery, 6 - lacrimal nerve and superior ophthalmic vein, 7 - frontal nerve, 8 - trochlear nerve, 9 - abducent nerve, 10 - nasociliary nerve, 11 - oculomotor nerve, 12 - middle meningeal artery, 13 - lesser petrosal nerve, 14 - greater petrosal nerve, 15 - posterior cerebral artery, 16 - anterior inferior cerebellar artery, 17 - posterior inferior cerebellar artery, 18 - vertebral artery, 19 - basilar artery, 20 - anterior spinal artery, 21 - hypoglossal nerve, 22 - spinal root of the accessory nerve, 23 - glossopharyngeal, vagus and accessory nerve, 24 - facial nerve and vestibulocochlear nerve, 25 - abducent nerve, 26 - trochlear nerve, 27 - superior cerebellar artery, 28 - oculomotor nerve, 29 - mandibular nerve, 30 - posterior communicating artery, 31 - maxillary nerve, 32 - ophthalmic nerve, 33 - internal carotid artery, 34 - anterior communicating artery